CHAPTER 10

Principles of minimal access surgery

Learning objectives

To understand:

- The principles of minimal access surgery
- The advantages and disadvantages of minimal access approaches
- The safety issues and indications for minimal access surgery
- The perioperative assessment of patients undergoing minimal access surgery
- Novel advances in minimal access surgery and its adjuncts
- The application of artificial intelligence to minimal access surgery

DEFINITION

Minimal access surgery is a product of modern technology and surgical innovation that aims to accomplish surgical therapeutic goals with minimal somatic and psychological trauma. This type of surgery has reduced wound access trauma and is less disfiguring than conventional techniques. It can offer cost-effectiveness to both health services and employers by shortening operating times, shortening hospital stays, improving operative precision compared with open surgery in some (but not all) cases and allowing faster recuperation.

History of minimal access surgery

The first experimental laparoscopic procedure was performed by Kelling in 1901. Jacobaeus performed the first thoracoscopy in 1910, again using a cystoscope; however, it took another 70 years before Steptoe in the UK developed laparoscopy for treatment of infertility and Mouret performed the first video-laparoscopic cholecystectomy in 1987. Since laparoscopic techniques became widely adopted in the mid-1990s, minimal access surgery has developed into a multidisciplinary approach that crosses all traditional specialty boundaries and serves the patient as a whole and not specific organ systems.

MINIMAL ACCESS APPROACHES

Laparoscopy

A rigid endoscope is introduced through a port into the peritoneal cavity. Full details of laparoscopy including the principles of pneumoperitoneum can be found in *Chapter 7*.

Thoracoscopy

A rigid endoscope is introduced through an incision placed between the ribs to gain access to the thorax. In the majority of cases, specialist anaesthetic support is required to ensure isolation of the lung on the side of surgery, enabling the patient to be ventilated only on the non-operative side. This is achieved through the use of right- or left-sided double lumen endotracheal tubes that comprise both a bronchial and a tracheal lumen. Usually there is no requirement for gas insufflation as the operating space is held open by the rigidity of the thoracic cavity. In specific cases, such as mediastinal tumour resection and diaphragmatic surgery, gas insufflation at low pressure (5–8 mmHg) may be applied. Further information on the general principles of thoracoscopy are found in *Chapter 60*.

Single-incision minimal access surgery

Single-incision minimal access surgery has varied in popularity with both strong advocates and others who are sceptical of any advantages. Single-incision laparoscopic surgery (SILS) involves insertion of all instrumentation through a multiple channel port via a single incision at the umbilicus. The benefits are that the incision, through a natural scar (the umbilicus), is virtually 'scarless' and that fewer port sites potentially reduces pain and lessens the risks of port site bleeding and the potential for port site hernia.

SILS requires specially manufactured multichannel ports and often roticulating instruments. It has most commonly been adopted in gallbladder and hernia surgery, although more

Georg Kelling, 1866–1945, surgeon, Dresden, Germany, performed the first 'celioscopy' on a dog in 1901 using air insufflation and a Nitze-cystoscope.
Hans Christian Jacobaeus, 1879–1937, physician, Karolinska Institutet, Sweden.
Patrick Christopher Steptoe, 1913–1988 gynaecologist, Oldham, UK, a pioneer of *in vitro* fertilisation.
Phillippe Mouret, 1938–2008, surgeon, Lyon, France.

complex colon and rectal surgery can be performed. There remains debate as to whether the increased procedural difficulty, steep learning curve and increased direct costs in terms of devices, instruments and operating time can be offset by significant clinical benefit.

Uniportal thoracic surgery requires less specialist equipment; many minor thoracic procedures are commonly performed using this technique. More complex resectional procedures are less commonly performed, largely because of technical complexity when compared with multiport techniques, which are on the whole very well tolerated.

Endoluminal endoscopy and natural orifice surgery

Flexible or rigid endoscopes are introduced into hollow organs or systems, such as the urinary tract, upper or lower gastrointestinal tract and the respiratory and vascular systems. Advances in endoluminal technology now enable more complex procedures to be completed endoscopically where previous transabdominal or transthoracic surgical resection would have been advocated. Examples include endoscopic submucosal resection of complex colonic polyps, transanal endoscopic microsurgery and endobronchial laser resection of tracheal pathology.

Natural orifice translumenal endoscopic surgery (NOTES) offers the opportunity for 'scar-free' surgery by performing entire procedures via natural body orifices. While these techniques have been applied in the pelvis, abdomen and thorax, technical limitations and safety concerns have limited adoption. Concern over closure of the visceral puncture site is the principal issue that has prevented widespread uptake, as transgastric and transcolonic closure of peritoneal entry sites in a safe manner remains problematic. In addition, there are significant cost and training implications that have limited more widespread adoption.

Perivisceral endoscopy

Body planes can be accessed even in the absence of a natural cavity. Examples are mediastinoscopy, retroperitoneoscopy and retroperitoneal approaches to the kidney, aorta and lumbar sympathetic chain. Some of these approaches have been in place for many years (cervical mediastinoscopy was first performed in 1959); however, the availability of novel videoscopes has enhanced visualisation, thus improving the safety and accuracy of dissection.

Extraperitoneal approaches to the retroperitoneal organs, as well as hernia repair, are now commonplace, further decreasing morbidity associated with manipulation of the visceral peritoneum. Other examples include subfascial endoscopic perforator surgery for ligation of incompetent perforating veins in varicose vein surgery and endoscopic harvesting of the saphenous vein for use in coronary artery bypass grafting.

Arthroscopy and intra-articular joint surgery

Arthroscopy was one of the earliest applications of endoscopic techniques, first being applied in the knee as early as the 1930s. In the 1950s Watanabe developed arthroscopic techniques that have evolved such that shoulder, wrist, elbow and hip arthroscopy is now commonplace. Novel approaches to smaller joints such as the temporomandibular and metatarsal joints are being developed.

Hybrid minimal access surgery

Hybrid surgery may utilise a combination of flexible and straight stick endoscopic approaches or a combination of open and endoscopic surgery.

Totally endoscopic hybrid approach

The diseased organ is visualised and treated by an assortment of endoluminal and extraluminal endoscopes and other imaging devices. In the abdomen, examples include the combined laparo-endoscopic approach for the management of biliary lithiasis, colonic polyp excision and several urological procedures, such as pyeloplasty and donor nephrectomy. In the thorax, navigational bronchoscopy with placement of fiducial markers has been employed as a means of marking lung nodules that can then be resected via a minimal access video-assisted approach. Cardiovascular surgeons have for some time employed hybrid technologies to facilitate catheter-based placement of cardiac valves, atrial devices and intravascular stents.

Hybrid techniques offer improved visualisation, facilitating the primary procedure to be carried out either via a smaller incision or a minimal access approach where otherwise open surgery would have been necessary. Such approaches may necessitate the availability of 'hybrid' theatre facilities, limiting this approach to tertiary centres where such technology is available (*Figure 10.1*).

Open and endoscopic hybrid approach

Hand-assisted laparoscopic surgery (HALS) is a well-developed technique. It involves the intra-abdominal placement of a

Figure 10.1 Modern hybrid theatre set-up (courtesy of Mr Kelvin Lau, Barts Thorax Centre, London, UK).

Masaki Watanabe, 1911–1995, orthopaedic surgeon, Tokyo, Japan, known as the 'founder of modern arthroscopy'.

hand or forearm through a minilaparotomy incision, while pneumoperitoneum is maintained. In this way, the surgeon's hand can be used as in an open procedure. It can be used to palpate organs or tumours, reflect organs atraumatically, retract structures, identify vessels, dissect bluntly along a tissue plane and provide finger pressure to bleeding points, while proximal control is achieved. This approach has been suggested to offer technical and economic efficiency when compared with a totally laparoscopic approach, in some instances reducing both the number of laparoscopic ports and the number of instruments required. Indeed, some advocates argue that if such an incision is necessary for extraction of the final specimen then HALS does not significantly increase surgical trauma over totally laparoscopic approaches. Furthermore, for those trained in open surgery it may be easier to learn and perform than totally laparoscopic approaches, subsequently improving patient safety. With the new generation of surgeons training in totally laparoscopic surgery it is likely that use of HALS will diminish, although it should remain part of the minimally invasive surgeon's armamentarium.

SURGICAL TRAUMA IN OPEN, MINIMALLY INVASIVE AND ROBOTIC SURGERY

Most of the trauma of an open procedure is inflicted because the surgeon must have a wound that is large enough to give adequate exposure for safe dissection at a target site. The wound is often the cause of morbidity, including infection, dehiscence, bleeding, herniation and nerve entrapment. Wound pain prolongs recovery time and, by reducing mobility, contributes to an increased incidence of pulmonary atelectasis, chest infection, paralytic ileus and deep venous thrombosis.

Mechanical and human retractors cause additional trauma. Body wall retractors can inflict localised damage that may be as painful as the wound itself. In contrast, during laparoscopy, the retraction is provided by the low-pressure pneumoperitoneum, giving a diffuse force applied gently and evenly over the whole body wall, causing minimal trauma.

Exposure of any body cavity to the atmosphere also causes morbidity through cooling and fluid loss by evaporation. The incidence of postsurgical adhesions is reduced by use of minimally invasive approaches because there is less damage to delicate serosal coverings. In the manual handling of intestinal loops, the surgeon and assistant disturb the peristaltic activity of the gut and provoke adynamic ileus.

While minimal access methods were initially established in elective surgery, the advantages have led to increased uptake for a number of emergency surgical procedures, including perforated viscus repair, such as omental patch repair of a peptic ulcer perforation, lavage of localised perforation of diverticular disease, intrathoracic debridement of empyema and pneumothorax and haemothorax surgery. More recently, some experienced surgeons have chosen to employ minimal access approaches to trauma situations for initial assessment and treatment in stable patients.

Summary box 10.1

Advantages of minimal access surgery

- Decrease in wound size
- Reduction in wound infection, dehiscence, bleeding, herniation and nerve entrapment
- Decrease in wound pain
- Improved mobility
- Decreased wound trauma
- Decreased heat loss
- Improved visualisation

LIMITATIONS OF MINIMAL ACCESS SURGERY

Minimal access surgery has limitations. A number of these have been addressed with advances in instrumentation and endoscopic systems; however, the basic principles remain. Surgical robots further address a number of these limitations but present novel challenges.

Endoscopic surgery

Lack of three-dimensional vision

To perform minimal access surgery with safety, the surgeon must operate using an imaging system that provides a two-dimensional (2D) representation of the operative site. The endoscope offers a whole new anatomical landscape, which the surgeon must learn to navigate without the usual 'open approach' clues that make it easy to judge depth. The instruments are longer and sometimes more complex to use than those commonly used in open surgery. This results in the novice being faced with significant problems of hand–eye coordination. There is a well-described learning curve for novice surgeons and experienced 'open' surgeons when adopting the minimally invasive approach. Simulation training and mentoring are required to attain competence.

Three-dimensional (3D) imaging systems are available but are expensive and currently are not commonplace. Many surgeons feel that endoscopic 3D technology does not yet offer the technical enhancement necessary to improve safety. Indeed, 3D technology has been associated with ergonomic problems such as headache without quantifiable benefit in terms of accuracy and time to perform directed tasks. Future improvements in these systems carry the potential to enhance manipulative ability in critical procedures, such as knot tying and dissection of closely overlapping tissues. There are, however, some drawbacks, such as reduced display brightness and interference with normal vision because of the need to wear specially designed glasses for some systems. It is likely that brighter projection displays will be developed; however, the need to wear glasses is not easily overcome. These factors currently limit stereoscopic straight stick endoscopic surgery, which has largely been superseded by the development of robotic technology incorporating 3D vision.

Increased operative time

Minimal access surgery can be more technically demanding and slower to perform than conventional open surgery. On occasion, a minimally invasive operation is so technically demanding that both patient and surgeon would be better served by conversion to an open procedure. Prolonged anaesthetic and operative times may negate a number of the beneficial effects of minimal access surgery and increase the risk of respiratory and wound complications as well as compression neuropathy and venous thromboembolism. It is vital for surgeons and patients to appreciate that the decision to convert to an open operation is not a complication but, instead, usually implies sound surgical judgement in favour of patient safety.

Control of bleeding and haemostasis

Haemostasis may be difficult to achieve endoscopically because blood may obscure the field of vision with reduced image quality owing to light absorption. Experienced surgeons may be able to manage a degree of bleeding via an endoscopic approach; however, this requires a significant degree of experience and skill to be achieved safely. Such scenarios are also reliant on an experienced assistant able to reduce visual loss through optimal camera positioning. It should be remembered that a situation of controlled conversion can easily become uncontrolled, negating any benefit a minimally access approach would have achieved.

Advanced electrosurgery/diathermy and laser technology have improved dissection precision and haemostatic efficacy in endoscopic surgery. Ultrasonic dissection and tissue fusion devices continue to evolve with incremental technical improvements and surgeons are increasingly familiar with their use. Some devices now combine the functions of three or four separate instruments, reducing the need for instrument exchanges during a procedure. This flexibility, combined with the ability to provide a clean, smoke-free field, facilitates dissection, improves haemostasis and reduces operating times.

Loss of tactile feedback

Minimal access surgery is associated with some loss of tactile feedback, although this is less with straight stick endoscopy than with robotic procedures. This is an area of ongoing research in haptics and biofeedback systems. Early work suggested that laparoscopic ultrasonography might be a substitute for the need to 'feel' in intraoperative decision-making. Rather than producing tactile feedback, endoscopic ultrasound provides a visual representation of structures that in open surgery would rely on palpation for accurate localisation and appraisal. Widely used examples include appraisal of nodal disease in cancer surgery and biliary tract exploration.

Tissue extraction

Large pieces of tissue, such as the lung or colon, may have to be extracted from the body cavity following resection. In some circumstances this significantly increases the surgical trauma of the procedure that could otherwise be carried out via two or three small port incisions. Although tissue 'morcellators, mincers and liquidisers' can be used in some circumstances, they have the disadvantage of disrupting gross specimen morphology and cannot be used in surgery for malignancy. Typically, extraction is performed by enlarging one incision so as to facilitate removal without disruption to the specimen. Strategies to reduce surgical trauma have been considered. These include removal of lung via a subxiphoid approach so as to reduce intercostal neuropraxia or natural orifice extraction of abdominal resection specimens. However, such approaches are themselves associated with different complications such as herniation and injury to structures outside the direct operative field.

While tumour implantation and localisation at port sites initially raised important questions about the future of the laparoscopic treatment of malignancy, large-scale trials have shown concerns to be minimised by appropriate tissue handling, separating any tumours by bagging, irrigation and protecting the extraction site.

Cost

Initially high consumable costs and factors such as surgical learning curve and high conversion rates led to increased costs of minimal access approaches compared with their open equivalents. This is now largely no longer the case for straight stick endoscopic surgery such as laparoscopy and thoracoscopy. Indeed, despite higher direct consumable costs, improvements in outcomes, hospital stay and general upscaling of the procedural volume have resulted in improved cost-effectiveness for many minimal access procedures.

Future reductions in the costs of image-processing technology will result in a wide range of transformed presentations becoming available. It should ultimately be possible for a surgeon to access any view of the operative region accessible to a camera and present it stereoscopically in any size or orientation, superimposed on past images taken in other modalities. Such augmented reality systems continue to improve and are discussed in more detail below.

Summary box 10.2

Limitations of minimal access surgery

- Lack of 3D vision
- Loss of tactile feedback
- Haemostasis
- Extraction of large specimens
- Learning curve and increased operative time
- Cost
- Reliance on new technologies

ROBOTIC SURGERY

A robot is a mechanical device that performs automated physical tasks according to direct human supervision, a predefined program or a set of general guidelines, using artificial intelligence (AI) technology. In surgery, robots can be used to assist surgeons to perform operative procedures, primarily in the form of automated camera systems and telemanipulator

systems, thus resulting in the creation of a human–machine interface. Reduced degrees of freedom of movement and difficult ergonomic positioning for the surgeon can limit the application of straight stick endoscopy to a number of specialties owing to a loss in surgical precision. This has driven the uptake of robotic surgical systems, currently existing as two main categories:

- **Teleoperated (master–slave) systems:** a surgeon performs an operation via a robot and its robotic instruments through a televisual computerised platform (where the surgeon is the master, i.e. the operator, and the robot is the slave). This may be via onsite connections or remotely through the internet or other digital channels – hence the publicity of 'operating on a patient from another country' (such 'remote' operations are currently rarely performed but their existence is established).
- **Active or semiactive systems: these are typically image-guided or pre-programmed.** In active systems, a surgical robot completes a pre-programmed surgical task. This is guided by preoperative imaging and real-time anatomical constraints and cues through the application of in-built navigation systems. In semiactive systems, the robotic device may be in part pre-programmed and in part surgeon driven.

History of robotic surgery

The first documented clinical robotic procedure was a computed tomography (CT)-guided brain biopsy performed in 1985 utilising the PUMA (Programmable Universal Machine for Assembly) 560 system. This was followed by the ROBODOC, a pre-programmed active robot that enabled precise preparation of the femoral implant cavity during hip replacement. The benefit of such a device was the ability to perform tasks to a high degree of accuracy, thus minimising error and variation. While this and other active surgical robots demonstrated a number of advantages, they were largely superseded by the advent of wider laparoscopy and thoracoscopy, which became increasingly commonplace across during the 1990s and 2000s.

In 1992, Computer Motion developed the AESOP (Automated Endoscopic System for Optimal Positioning) system, which mounted the endoscopic camera on a single robotic arm, allowing the surgeon to control it remotely via voice command. The system was widely used in cholecystectomy and hernia surgery and for harvesting the mammary conduit in coronary artery bypass. This was followed by the development of the ZEUS robot in 1996, a master–slave teleoperated system that provided three robotic arms, one for the voice-controlled endoscope and two further instrument arms. The surgeon was positioned at a remote console and the device was capable of motion scaling and tremor correction, facilitating its use for microsurgical procedures. ZEUS was used for the first fully endoscopic robotic surgical procedure, the reanastomosis of a Fallopian tube in 1998. The first remote surgical procedure was performed in 2001, also utilising the ZEUS system. Here a cholecystectomy was performed on a patient in Paris by a surgeon in New York, demonstrating the feasibility of remote operating. ZEUS was discontinued in 2003 after the merger of Computer Motion with Intuitive Surgical.

The current era of surgical robots is dominated by the da Vinci® surgical system, which was first approved for clinical use in 2000. The system offers a number of advantages, including 3D surgical vision, EndoWrist® precision instruments, tremor reduction, motion scaling and improved ergonomics. The initial system was released in 1999 and provided three robotic arms, one of which held the endoscope. This was upgraded to the da Vinci S (2006), the da Vinci Si (2009) and subsequently the da Vinci Xi in 2014 (*Figure 10.2*). With each iteration came improvements in vision and instrumentation, along with which came integrated fluorescence imaging. More recently, novel technologies include the development of a single port system (da Vinci SP), which combines multijointed wristed instrumentation with a wristed camera through a single port to further improve dexterity and minimise surgical trauma.

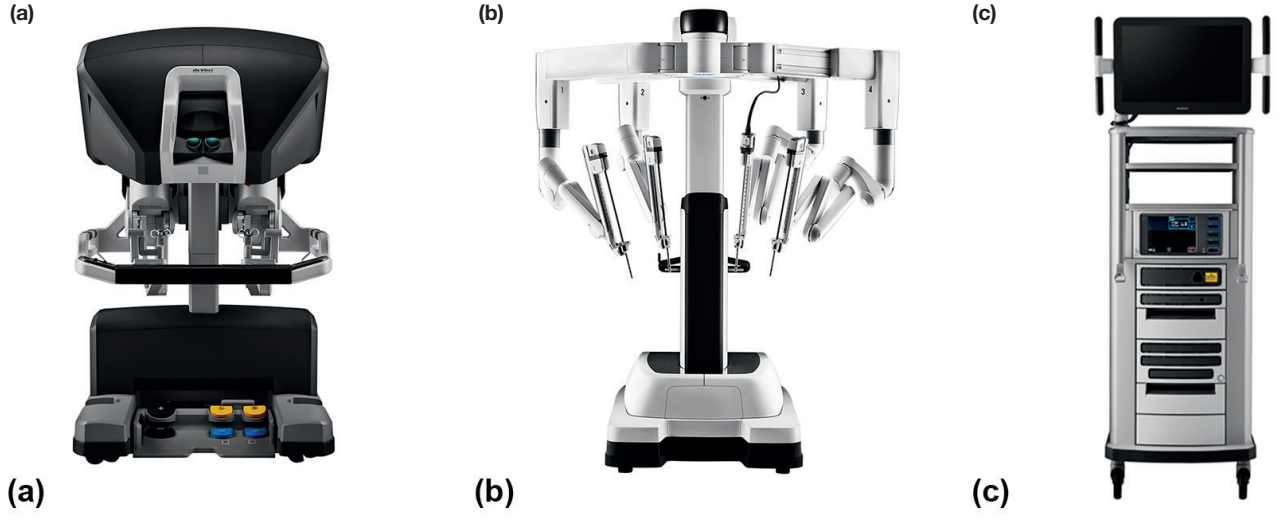

Figure 10.2 The da Vinci Xi system: (a) surgeon console; (b) da Vinci Xi robot; (c) vision cart (courtesy of Intuitive Surgical).

Advantages of robotic surgery

Surgical robots have been considered to offer many benefits, which have arisen as a result of new technology in lenses, cameras and computer software. Just as laparoscopic surgery benefited from advances in light technology allowing the targeted transmission of light down tubing, robotic surgery benefits from computer integration of mechanical (surgical) arms that have paved the way for computer-integrated surgery.

Vision

Modern robotic camera systems offer 3D high-definition imaging, providing stereoscopic vision with true depth perception that enhances the visualisation of tissue planes and key structures. Multiport systems typically employ a rigid endoscope with or without angulation. As with conventional endoscopes, angulation to 30° allows for a wider range of vision through manipulation of the camera position, which, in the case of robotic surgery, can be controlled by the surgeon at the console or, if required, by the assistant at the bedside. A reference horizon is commonly provided to the surgeon at the console system so as to maintain orientation throughout the procedure. More recently, modern single-port systems such as the da Vinci SP employ a wristed camera system that, in combination with fully wristed instruments, may allow for operative triangulation while at the same time maintaining a small, single skin incision.

Manoeuvrability, motion scaling and tremor suppression

Improved manoeuvring as a result of the 'robotic wrist' in some systems allows for up to seven degrees of freedom, thus improving dexterity for the surgeon. This has particular benefits in fields with significant space restraints such as transoral surgery, where conventional laparoscopy has limited applicability. Furthermore, the increased dexterity of surgical robots may facilitate a minimal access approach to more complex procedures where the technical difficulty of applying conventional laparoscopy may be prohibitive. As the motion of the surgeon's hand is translated to the 'slave' motion of the robotic arm, modern surgical robots are able to scale down large external movements of the surgical hands to limited internal movements. At the same time, the computer may filter out tremor in the surgeon's hands, thus ensuring stability of the instrument tips and enhancing surgical precision.

Ergonomics

Although the advent of straight stick laparoscopic surgery had many advantages for the patient, for the surgeon there was a trade-off in terms of operative ergonomics. Increased operative time in addition to unergonomic positioning can result in significant physical discomfort for the surgeon. This is particularly true in specialties such as bariatric surgery, where the patient's body habitus and the use of long, fulcrumed instruments puts further strain on the surgeon's back, neck and upper arms. The advent of robotic surgery vastly improves upon the ergonomic environment for the surgeon; in the case of many of the current master–slave systems, allowing for the surgeon to be seated at a console remote from the operating table (*Figure 10.3*). The console positioning can be optimised to fit the individual profile of the operator, thus reducing physical stress and fatigue. The enclosed console system of many robotic systems also provides the advantage of surgical isolation from external distractions that may impact on the operator's concentration. The disadvantage is reduced awareness of non-verbal communication, thus highlighting the importance of team training and regular verbal cues.

Motion compensation

Although not commonplace in current clinical practice, robotic surgical systems may in future provide motion compensation to facilitate surgery on a moving target. Examples where this may be beneficial are in beating heart cardiac surgery, such as coronary artery bypass grafting and mitral valve repair. In this setting, the increased dexterity of robotic surgery combined with removing the need for cardioplegia and cross-clamping may be particularly beneficial in terms of reducing the post-operative inflammatory response and improving its associated morbidity.

Disadvantages of robotic surgery

Cost

Robotic surgery remains more costly than minimally invasive alternatives. Through upscaling of use between surgical specialties, the direct costs of purchasing a novel robotic system can be partially offset; however, consumable costs remain high. When compared with open techniques, robotic surgical procedures can reduce hospital stay, thus in part offsetting this expenditure; however, it remains difficult to demonstrate significant improvement in length of stay or clinical outcomes when compared with other minimally invasive alternatives. Another consideration is the increased operating time and overall learning curve requirement when establishing a robotic surgical programme. While some specialties have reported shorter learning curves than in the early days of laparoscopic surgery, this is highly heterogeneous, across both specialties and practitioners. Furthermore, although shared interspecialty

Figure 10.3 Robotic theatre set-up demonstrating the da Vinci Xi system. The surgeon and trainee surgeon are positioned at joint consoles remote from the operating table with the surgical assistant and scrub nurse at the bedside (courtesy of Mr Tom Routledge, Guy's and St Thomas' NHS Foundation Trust, London, UK).

use increases cost-effectiveness for the institution, it also consequently reduces the access opportunities for each individual user, potentially prolonging the learning curve.

Uptake of robotic surgery

Many surgical specialties have embraced robot-assisted techniques, including general surgery, cardiothoracic surgery, urology, orthopaedics, ear, nose and throat surgery, gynaecology and paediatric surgery. Specialties that use microsurgical techniques also benefit from this technology. Current robotic systems were designed to offer multifunctionality, including multianatomy and specialty capability in both operating theatre and remote environments. Currently, despite a small number of reports of remote surgical procedures, robotic surgery remains focused on in-house operating.

New entrants

In 2017, Intuitive Surgical released the da Vinci X, a low-cost entry point in its robotic surgical portfolio that includes features of the Xi while sacrificing some flexibility in terms of multi-quadrant surgery. In the same year, Korean company Meere gained a licence for the use of its surgical robot, the REVO-I, by the local Ministry for Food and Drug Safety. Similar to the da Vinci, this four-arm robot is mounted on a single cart. The surgeon is seated at an open vision cart and, by use of 3D glasses, can achieve three-dimensional high-definition (3D-HD) vision. In March 2019, CMR Surgical received a European CE mark for its novel modular robot, the Versius (*Figure 10.4*). This system incorporates individual cart-mounted modular robotic arms that can be configured to fit the procedure and the operating room environment. The design differs from other robotic arms in that it aims to more closely mimic a human arm, improving freedom of port placement. Its vision cart similarly allows for ergonomic operating with 3D-HD vision, through the use of 3D glasses.

Bridging the gap between laparoscopic and robotic surgery the Senhance® robotic system received its CE mark in 2016. In order to reduce cost and sustain familiarity with conventional laparoscopy, the system uses independent robotic arms mounted on separate carts that can be placed in accordance with the procedure required. The system utilises reusable non-wristed instruments that can be inserted through standard laparoscopic trocars so as to reduce consumable cost. This system also creates familiarity with conventional laparoscopy and facilitates hybrid techniques where this may be beneficial. Surgery is enhanced though a 3D-HD system with the use of 3D glasses and eye-tracking camera control.

Figure 10.4 The Versius robotic system (courtesy of CMR Surgical).

As the field of robotic surgery continues to expand and innovate, there also remain a number of systems in development that are not yet approved for clinical use. Examples similar to existing technologies include the Medtronic Hugo Robotic-Assisted Surgery (RAS) system, which was launched in late 2019. This modular system aims to provide a lower cost alternative by means of a more readily upgradeable model that may be used flexibly across surgical specialties and procedures. Moving forward, companies such as Verb Surgical strive to build on the currently dominant master–slave model, incorporating robotic autonomy and machine learning. While this may in time revolutionise robotic surgery, such technologies remain in the early phase of development.

Direct robotic systems and hybrid robotic surgery

In addition to the remote master–slave platform design, direct robot systems also exist. Each of these systems offers different advantages to the operating surgeon, ranging from reducing the need for assistants and providing better ergonomic operating positions to providing experienced guidance from surgeons not physically present in the operating theatre. Examples include:

- tremor suppression robots;
- active guidance systems;
- articulated mechatronic devices;
- force control systems;
- haptic feedback devices.

PERIOPERATIVE PLANNING FOR MINIMAL ACCESS SURGERY

Preparation of the patient

Although the patient may be in hospital for a shorter period, careful preoperative management is essential to minimise morbidity. Recognition of patient- or procedure-related factors that may in turn complicate a minimal access approach is vital to optimise outcomes.

History

Patients must be fit for general anaesthesia and open operation if necessary. Potential coagulation disorders are particularly dangerous in minimal access surgery where options for haemostasis may be more limited. A prior history of surgical intervention in the same area is vitally important and should be carefully documented, so as to best predict factors such as adhesions that may preclude a minimal access approach. Previous oncological treatment can also create a more hostile surgical environment and an appropriate threshold for conversion to open access should be set prior to the procedure and communicated clearly with the patient.

Summary box 10.3

Preparation for minimal access surgery

- Overall fitness: cardiac arrhythmia, lung function, medications, allergies
- Previous surgery or oncological intervention: scars, adhesions
- Body habitus: obesity, skeletal deformity
- Normal coagulation
- Thromboprophylaxis
- Informed consent
- Operative difficulty is predicted when possible with appropriate risk model
- Appropriate theatre time and facilities are available (especially important for robotic cases)

Examination

Routine preoperative physical examination is required as for any major operation. Although, in general, minimal access surgery allows quicker recovery, it may involve longer operating times and carbon dioxide insufflation in both the chest and abdomen may provoke cardiac arrhythmias. Severe chronic obstructive airways disease and ischaemic heart disease may be contraindications to a minimal access approach. Moderate obesity does not increase operative difficulty significantly, but morbid obesity may require specialist instrumentation and trocars. Patients with a particularly low body mass index and small body habitus may present separate challenges in terms of port placement, particularly when adopting a robotic approach. Severe spinal deformity including kyphosis and scoliosis may present problems in terms of positioning as well as impact on overall recovery if there are associated problems with sputum clearance and mobility.

Prophylaxis against thromboembolism

Venous stasis induced by the reverse Trendelenburg position during laparoscopic surgery coupled with prolonged duration of operation are risk factors for deep vein thrombosis. Subcutaneous low-molecular-weight heparin and antithromboembolic stockings should be used routinely in addition to pneumatic calf compression during the operation. Patients already taking anticoagulation should have this stopped temporarily or, where appropriate, be converted to intravenous or subcutaneous heparin, depending on the underlying condition and local thromboprophylaxis protocols. In most cases patients can continue on aspirin when the benefits outweigh the slight increase in bleeding potential.

Urinary catheters and nasogastric tubes

In the early days of minimal access surgery, routine bladder catheterisation and nasogastric intubation were advised. Most surgeons now omit these in favour of enhanced recovery, which has demonstrated benefits in terms of both length of stay and morbidity outcomes. It remains essential to check that the patient has fasted and has recently emptied their bladder, particularly before creating pneumoperitoneum for minimal access surgery approaches to the abdomen.

Informed consent

It is essential that the patient understands the nature of the procedure, the risks involved and, when appropriate, the alternatives that are available. A locally prepared explanatory booklet concerning the minimal access procedure to be undertaken is extremely useful (*Chapter 14*). The patient should understand that the procedure may be converted to an open operation. Common complications should be mentioned, such as shoulder tip pain and minor surgical emphysema, as well as rare but serious complications, such as inadvertent visceral injury from trocar insertion or diathermy. Patients may also have specific questions or requests in terms of the application of minimal access surgery. It is important to be considerate and address these. Some patients remain concerned about the application of technology, particularly robotics, to their care and it is important to ensure they understand and agree with the proposed surgical approach.

THEATRE SET-UP AND TOOLS

Operating theatre design is key to efficiency. Modern theatres are designed with moveable booms for video, diathermy and laparoscopic equipment with at least two high-resolution, high-definition (HD) or ultra-high-definition (4K) monitors, a carbon dioxide supply and flow monitor and appropriate audiovisual kit (*Figure 10.1*).

Image quality is vital to the success of minimal access surgery. New camera and lens technology allows the use of smaller cameras while maintaining excellent resolution. Automatic focusing and charge-coupled devices (CCDs) are used to detect different levels of brightness and adjust for the best image possible.

Efficient teamwork is crucial for high-quality surgery and quick yet safe turnover. This is particularly important in robotic surgery, where verbal interaction between all team members is paramount throughout the procedure. The robotic team must carefully rehearse protocols for both controlled and uncontrolled conversion in the event of emergency.

GENERAL INTRAOPERATIVE PRINCIPLES

Many minimal access procedures have a unique set of procedural steps that may often be in a distinctly different sequence from those of the open alternative.

Methods for creating a pneumoperitoneum are described in *Chapter 7*. Preoperative evaluation is necessary to assess the type and location of surgical scars and potential for perivisceral adhesions. In the setting of redo surgery, trocar insertion may be complex and should be performed by an open approach with direct visualisation on entry to the body cavity (abdomen

Friedrich Trendelenburg, 1844–1924, Professor of Surgery successively at Rostock (1875–1882), Bonn (1882–1895), Leipzig (1895–1911), Germany. The Trendelenburg position was first described in 1885.

or thorax). Before trocar insertion, the introduction of a fingertip helps to ascertain penetration into the body cavity and allows adhesions to be gently removed from the entry site. The endoscopic camera may be used as a blunt dissector to tease adhesions gently away and form a tunnel towards the quadrant where the operation is to take place. With experience, the surgeon learns to differentiate visually between thick adhesions that should be avoided and thin adhesions that would lead to a window into a free area.

In obese patients the location of some of the ports may need to be modified and, in some instances, larger and longer instruments may be necessary. It is important to recognise this preoperatively to ensure that adequate measures are put in place to ensure safe and efficient surgery when the patient arrives. It is also important to consider the weight and dimension restrictions of the operating table. In some cases, specialist operating tables will be required (*Chapter 68*).

Operative problems

Intraoperative perforation of a viscus or vascular injury

Perforation of any viscus, such as bowel, is a potential hazard that may occur inadvertently and go unrecognised or be of a severity that may require emergency conversion. The added time required for this to take place may result in increased blood loss and haemodynamic instability that would not have occurred should the same injury have occurred in an open setting. With surgical experience, education, preparation and patient selection many of these emergencies and their resultant complications can be avoided. It is vital for the surgical team to both recognise its own limitations and continually reflect throughout the procedure on the surgical progress and operative difficulty.

Bleeding

Bleeding is the most common cause of conversion to open surgery. The impact of light absorption is particularly important in robotic surgery, and regular haemostasis is paramount to facilitate dissection and surgical progress. Risk factors that predispose to increased bleeding include:

- liver disease impacting on the production of vitamin K-dependent clotting factors, e.g. cirrhosis, autoimmune liver disease;
- inflammatory conditions (acute cholecystitis, diverticulitis);
- patients on anticoagulants;
- coagulation defects: these may be contraindications to both open and minimal access surgery and require thorough discussion with haematology colleagues to determine, where possible, how to optimise the patient for surgery.

Damage to a large vessel requires immediate assessment of the magnitude and type of bleeding. It is paramount that as soon as bleeding is identified this is communicated clearly to all members of the theatre and anaesthetic team. There should be a relatively low threshold for early conversion; however, this will depend on the expertise of the operating team. It is pertinent to achieve early control by whatever means necessary. When the bleeding vessel can be identified and grasped, control may be achieved by clipping, stapling or use of an energy device, depending on vessel size. Occasionally suturing may be possible; however, this may be significantly more complex via a minimal access approach. When the vessel is not identified, compression should be applied immediately with a blunt instrument, a cotton swab or with the adjacent organ. Good suction and irrigation are of utmost importance. Once the area has been cleaned, pressure should be released gradually to identify the site of bleeding. Insertion of an extra port may be required. There should be no delay in converting to an open procedure when necessary. This is of particular importance in robotic surgery as some or all of the robotic arms may need to be urgently undocked to facilitate the surgeon gaining bedside access to the patient. The bedside assistant should be confident to perform this process. It is sometimes appropriate for a single robotic arm to be left in place to help maintain pressure on the bleeding vessel while direct access is achieved. Alternatively, pressure may be maintained via an assistant port (if present), allowing the robot to be undocked completely and removed from the surgical field.

Bleeding from organs encountered during surgery

Excessive retraction can tear a visceral surface, resulting in bleeding. This is particularly so in robotic surgery, where instrument graspers have a small surface area, increasing the potential for injury to retracted tissue. Here rolled swabs may be inserted into the surgical field and held within the grasper, producing a larger surface for retraction and reducing tissue injury. Surgicel® (absorbable fibrillar oxidised cellulose polymer) or other clot-promoting strips, tissue glues or other haemostatic agents may also be used to aid haemostasis, e.g. from the gallbladder bed during cholecystectomy.

Bleeding from a trocar site

Bleeding from the trocar sites is usually treated by localised diathermy or applying upwards and lateral pressure with the trocar itself. Considerable bleeding may occur if a vessel such as the inferior epigastric or intercostal artery is injured. Haemostasis can be accomplished either by pressure or by suturing the bleeding site. Devices such as the EndoClose™ may also be used to apply transabdominal sutures under direct laparoscopic view to close port sites that bleed.

When a bleeding vessel cannot be easily identified, mass ligation of the vessel around the port site can be performed. This manoeuvre is accomplished by extending the skin incision by 3 mm at both ends of the bleeding trocar site wound. Two figure-of-eight sutures are placed in the path of the vessel at both ends of the wound (*Figure 10.5*). Alternatively, pressure can be applied using a Foley balloon catheter. The catheter is introduced into the abdominal cavity through the bleeding trocar site wound, the balloon is inflated and traction is placed on the catheter, which is bolstered in place to keep it under tension. The catheter is left *in situ* for 24 hours and then removed.

If significant continuous bleeding from the falciform ligament occurs, haemostasis is achieved by percutaneously inserting a large, straight needle at one side of the ligament. A monofilament suture attached to the needle is passed into the abdominal cavity and the needle is exited at the other side

of the ligament using a grasper. The loop is suspended and compression is achieved. Maintaining compression throughout the procedure usually suffices. After the procedure has been completed, the loop is removed under direct laparoscopic visualisation to ensure complete haemostasis.

Evacuation of blood clots

Careful haemostasis is important as even small, localised pools of blood or clot absorb light and can significantly impair the surgical view. Carefully directed suction is usually sufficient in open cases; however, suction may be problematic in laparoscopic and robotic procedures that are reliant on carbon dioxide insufflation to maintain the surgical field. It is important that suction is applied below a fluid level, or, if used in the operative field, only in short bursts as required. Should tissue be inadvertently sucked into the end of the suction device, the tubing can be kinked to allow the tissue to drop away before removing. Rolled swabs or sponges can be used to remove blood from the surgical field without need for suction (*Figure 10.6*). These can also be used for gentle retraction, minimising tissue damage and thus further reducing blood loss. Such swabs may be inserted and removed via a 15-mm assistant port or in some cases a 12-mm robotic trocar with the port cap removed. Care should be taken to avoid carbon dioxide loss during extraction. Finally, the surgeon may choose to use a specially designed robotic sucker that integrates with the robotic system. Alternatively, non-wristed suction can be provided via an assistant port if included in the operative set-up.

Principles of electrosurgery during laparoscopic surgery

Inadvertent electrosurgical injuries during minimal access surgery are potentially serious and are often unrecognised at the time. The vast majority occur following the use of monopolar diathermy. For conventional laparoscopy, the overall incidence is thought to be between one and two cases per 1000 operations. Injuries can occur through inadvertent touching or grasping of tissue during current application; direct coupling between tissue and a metal instrument that is touching the activated probe; insulation breaks in the laparoscopic or robotic instruments; direct sparking from the diathermy probe; or current passage from recently coagulated, electrically isolated tissue. Bipolar diathermy is safer and should be used in preference to monopolar diathermy, especially in anatomically crowded areas. If monopolar diathermy is to be used, important safety measures include attainment of a perfect visual image, avoiding excessive current application and meticulous attention to insulation. Alternative methods of performing dissection, such as the use of ultrasonic devices, may improve safety.

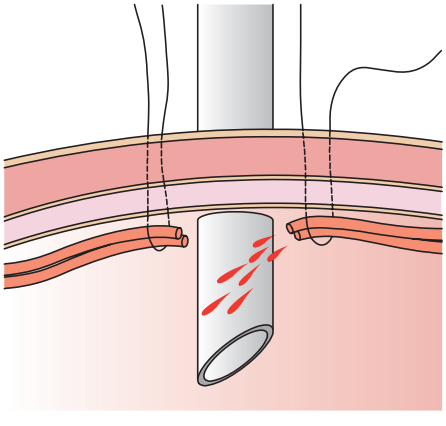

Figure 10.5 Management of bleeding from a surgical trocar site.

POSTOPERATIVE CARE

The postoperative care of patients after minimal access surgery is generally straightforward, with a low incidence of pain or other problems when compared with their open counterparts. It is a good general rule that if the patient develops a fever or tachycardia, or complains of severe pain at the operation site, something is wrong and close observation or intervention is necessary (see also *Chapter 24*).

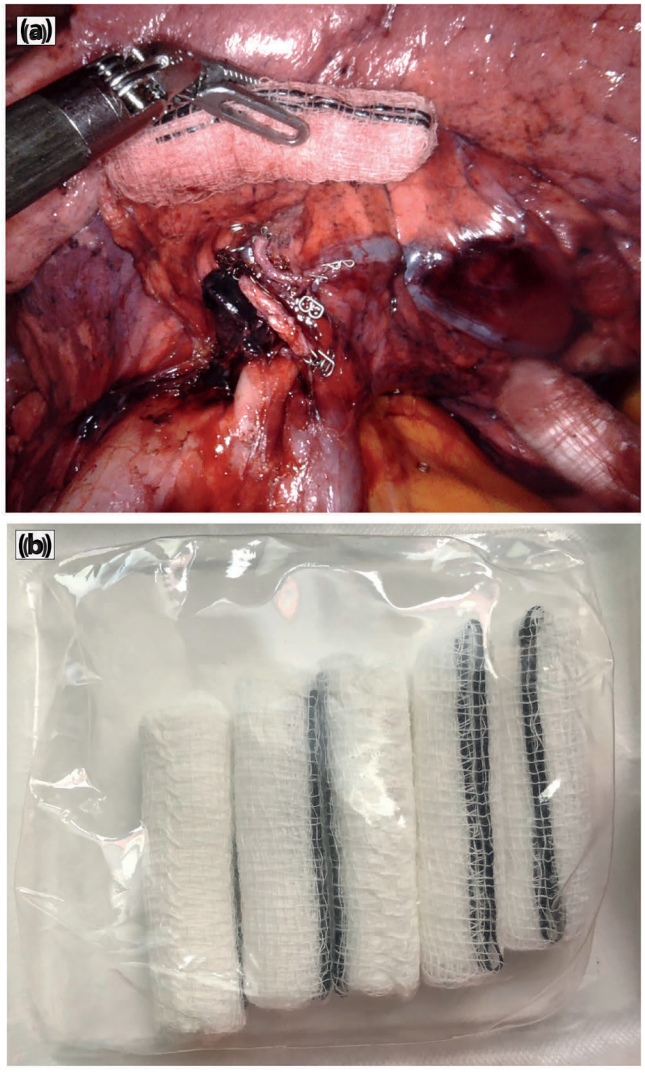

Figure 10.6 Use of rolled swabs for retraction of the lung during pulmonary lobectomy (courtesy of Mr Tom Routledge, Guy's and St Thomas' NHS Foundation Trust, London, UK).

Nausea

About half of patients experience some degree of nausea after minimal access surgery. It usually responds to an antiemetic, such as ondansetron, and settles within 12–24 hours. It is made worse by opiate analgesics and these should be rationalised or avoided where at all possible.

Shoulder tip pain

Patients should be warned about this preoperatively and informed that the pain is referred from the diaphragm and that it is not due to a local problem in the shoulders. It can be at its worst 24 hours after the operation. It usually settles within 2–3 days and is relieved by simple analgesics, such as paracetamol.

Port site pain and numbness

Pain in one or other of the port site wounds is not uncommon and is worse if there is haematoma formation. It usually settles very rapidly. In the case of thoracoscopy, intercostal nerve pain may be more common in those with smaller intercostal spaces. Nerve blockade by means of directed local anaesthesia is effective at reducing pain and the need for opiate medication in the immediate postoperative period. Increasing pain after 2–3 days may be a sign of infection and, with concomitant signs, antibiotic therapy is occasionally required. Occasionally, herniation through a port may account for localised pain and should be considered, particularly if occurring late with a relevant preceding history (e.g. coughing). Failure of a patient to follow the expected recovery pathway should prompt senior review with appropriate imaging and relook surgery if considered necessary.

Analgesia

The type and extent of analgesic requirement will depend on both the patient and procedural factors. Prior experience of opiate analgesia may increase patient tolerance to similar agents, necessitating larger doses. There is also evidence to suggest that those patients struggling with chronic pain preoperatively often present a more complex postoperative analgesic problem. The extent and region of surgery will also dictate the analgesic regimen. For example, even minimal access thoracic surgical procedures commonly require patient-controlled opiate analgesia with or without local nerve blockade (intercostal or paravertebral) in the initial 48 hours after surgery. This may be avoided for some abdominal surgery by careful use of non-steroidal agents and paracetamol. Opiate analgesics cause nausea, impair gut motility and should be avoided unless the pain is very severe. When pain is disproportionate to the presenting problem, suspect a complication (see also *Chapter 23*).

Orogastric or nasogastric tube

An orogastric or nasogastric tube may be placed for some abdominal surgery if the stomach is distended and obscuring the view. It is not necessary in all cases and is very rarely used in other minimal access surgery. Where possible, it should be removed as soon as the operation is over and before the patient regains consciousness. This is most commonly used in bariatric and oesophagogastric surgery, where a larger (32F or 34F) tube is used.

Oral fluids

There is no significant ileus after minimal access surgery, except in abdominal resectional procedures, such as colectomy or small bowel resection. Patients may resume oral fluids as soon as they are conscious; they usually do so 4–6 hours after the end of the operation.

Oral feeding

Provided that the patient has an appetite, a light meal can be taken 4–6 hours after the operation. Some patients remain slightly nauseated at this stage, but almost all eat a normal breakfast on the morning after surgery. Subsequently a balanced diet is recommended in most cases and where specific procedural recommendations are needed these should be clearly communicated to both the patient and relatives with appropriate dietetic referral made.

Urinary catheter

The requirement for a urinary catheter depends on the operation. In shorter (<4 hours) minimal access procedures a urinary catheter is not usually required. If a urinary catheter has been placed in the bladder during an operation with likely short stay, it can be removed before the patient regains consciousness if the procedure has been uneventful. Postoperatively it is important to check that the patient has been able to pass urine and empty their bladder without difficulty. When there is uncertainty point-of-care bladder scanning can assess residual bladder volume.

Drains

The use of postoperative drains depends on the operation performed. Drain output should initially be documented at least hourly or more regularly in the event of concern regarding high drain output. Given the heterogeneity of drainage systems available it is paramount that nursing staff are familiar with the system used. The exact location and size of any drains should be clearly documented in the operation notes and the tubing labelled accordingly. This avoids inadvertent removal of the wrong drain or confusion for the ward team. Continued blood loss from a drain is an indication for re-exploration and should be immediately highlighted to the operating surgeon.

DISCHARGE FROM HOSPITAL

The discharge of patients is based on clinical indicators and the patient's fitness for recuperating in a non-hospital environment. One of the core drivers for the application of minimally invasive surgery is an earlier recovery and therefore discharge from hospital. Patients should not be discharged until they are comfortable, have passed urine and are eating and drinking

Summary box 10.4

Principles of minimal access surgery

- Meticulous care in the creation of a pneumoperitoneum
- Controlled dissection of adhesions
- Adequate exposure of operative field
- Avoidance and control of bleeding
- Avoidance of organ injury
- Avoidance of diathermy damage
- Vigilance in the postoperative period

satisfactorily. They should be told that if they develop worsening pain or other severe symptoms they should return to the hospital or to their general practitioner. Even for more major cases, some units have demonstrated safe and feasible protocols for a 23-hour stay.

Skin sutures

If non-absorbable sutures or skin staples have been used, they can be removed from the port sites after 7–10 days.

Mobility and convalescence

Patients can get out of bed to go to the toilet as soon as they have recovered from the anaesthetic and they should be encouraged to do so. Such movements are remarkably pain free when compared with the mobility achieved after an open operation. Similarly, patients can cough actively and clear bronchial secretions, and this helps to diminish the incidence of chest infections.

FURTHER DEVELOPMENTS

Augmented reality and minimal access surgical adjuncts

The future of minimal access surgery will almost certainly feature more advanced applications of adjuncts to facilitate anatomical recognition and the localisation of pathology. These are becoming commonplace in both video-assisted and robotic-assisted procedures.

Augmented reality

Augmented reality by definition comprises the fusion of projected computerised images with a real environment. In surgery, this involves the application of real-time imaging or other data overlaid via computer processing software onto the surgical field. Such technology may be particularly beneficial in minimal access surgery where the localisation of pathology and identification of anatomy may be more difficult than in open surgery because of the lack of digital palpation of the relevant structures. At an elementary level, examples include the use of indocyanine green for immunofluorescent localisation of tumours as well as vascular, bronchial or lymphatic structures. When bound to plasma proteins, indocyanine green emits light with a peak wavelength of around 820–830 nm on illumination with near-infrared light. Through use of a specifically designed HD camera and software system with imposed pseudo-colour, areas of differential tissue density and vascular supply can be detected clearly without the need for digital palpation, thus facilitating complete resection and clear surgical margins. Its use is now well established in procedures such as minimal access liver, lung, renal and prostatic resections, and its role in other specialties such as colorectal surgery is also under investigation. The technology can be integrated into both video-assisted and robotic-assisted surgical procedures and is available within the da Vinci Xi and X robotic surgical systems as the Firefly® mode, which can be turned on as required from the surgical console (***Figure 10.7***).

Another role for augmented reality in minimal access surgery is the overlay of imaging beside or directly onto the surgical field, 'navigating' the surgeon to the site of interest without the need to look away from the patient to review imaging. Such navigational techniques originated in image-guided diagnostics, enabling identification of pathology in areas more difficult to reach anatomically. Through increasing adoption of hybrid theatre complexes, these approaches may be utilised for both diagnosis and treatment in a single setting. An example is the use of navigational bronchoscopy to identify, diagnose and treat difficult to reach or small lung nodules. Preoperative planning CT scan is reconstructed by specialist software. The result is a 3D 'road map' of the bronchial tree and a side-by-side picture of real-time endobronchial images with those from the imaging system (***Figure 10.8***). The surgeon is then guided directly along the airway to the lesion of interest that can be biopsied with on-site frozen section. Where the lesion is resectable but difficult to localise, a fiducial marker may be placed to enable localisation under fluoroscopy guidance in a second-stage procedure performed in a hybrid theatre (***Figure 10.9***). Where resection is not possible, ablation or other treatment may be offered in the same setting, both reducing surgical invasiveness and increasing the provision of curative surgery to patients who may not otherwise be candidates for resection.

An area of interest is the application of head-mounted displays and eyeglasses to minimal access surgery. Although the majority of applications remain in the realm of simulation and training, the promise of real-time image guidance by means of multiplanar or imaging overlay of the surgeon's view is particularly attractive. Head-mounted displays may also provide data display or communication tools, reducing the need for the surgeon to look away from the operative field and allow real-time guidance by a trainer or proctor. To date, clinical application is limited owing to time lag, the need for high-speed wireless Internet or Bluetooth connection and device weight and battery life; application to minimal access surgery remains under development.

THE FUTURE

Minimal access surgery has changed surgical practice; however, it has not changed the nature of disease. The basic principles of good surgery still apply, including appropriate case selection, excellent exposure, adequate retraction and a high level of technical expertise. Endoscopic and robotic surgery training is

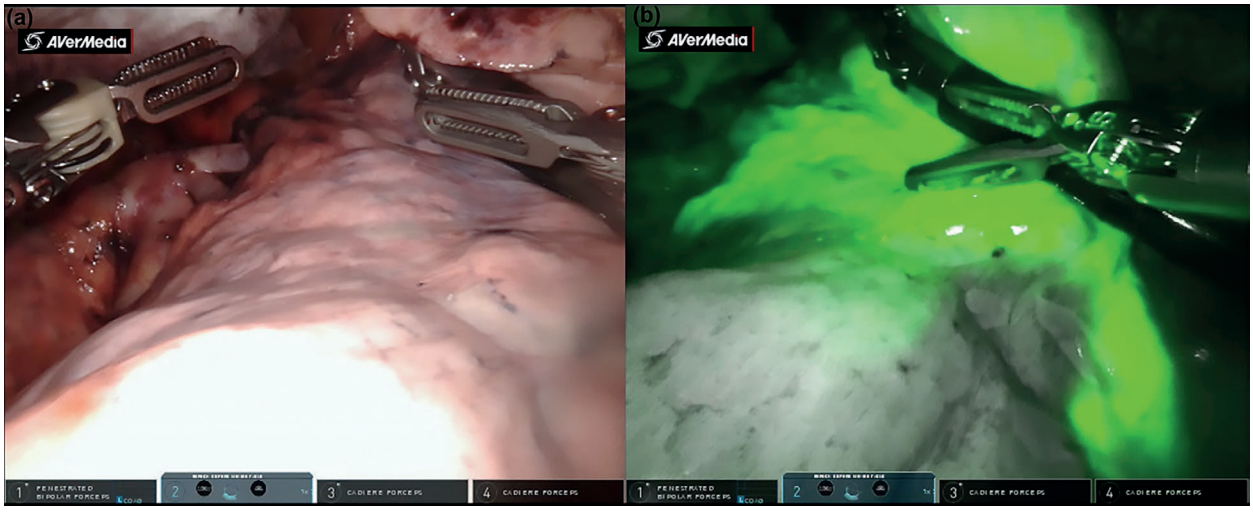

Figure 10.7 Robotic-assisted lung segmentectomy utilising indocyanine green administered endobronchially to highlight the segment for resection. (a) Robotic dissection of the superior (S6) segment. (b) Indocyanine green immunofluorescence of the marked segment, enabling clear identification of the area for resection.

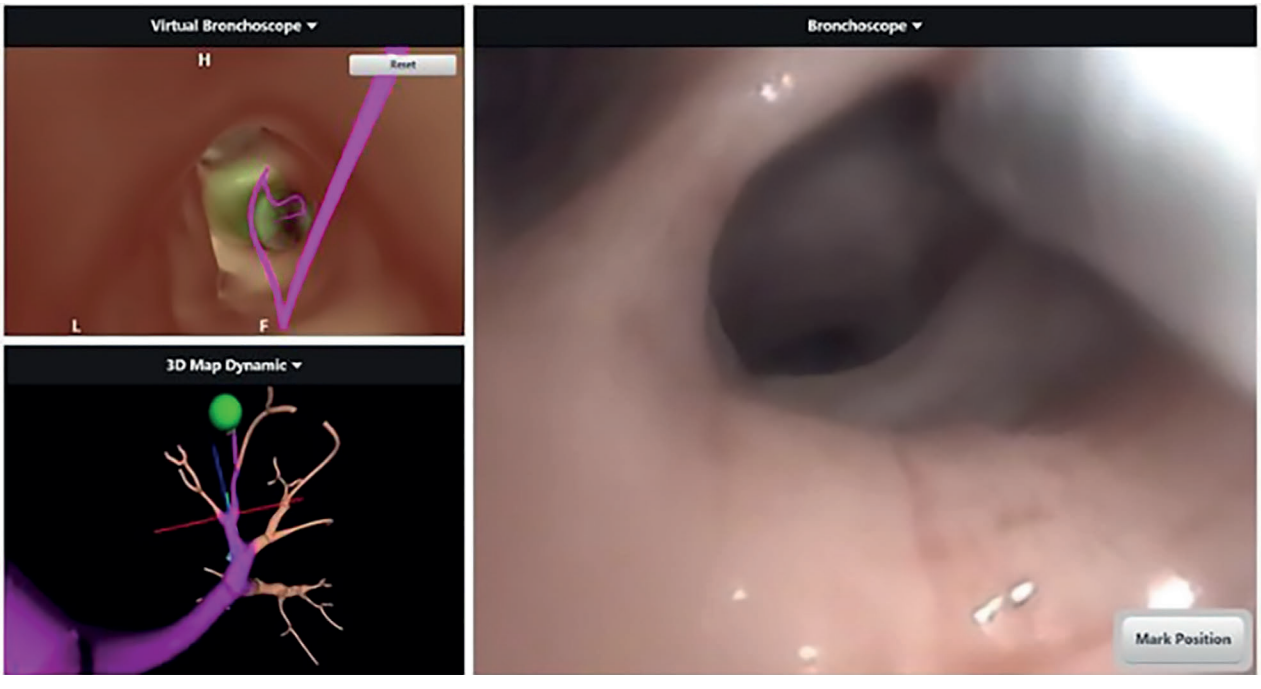

Figure 10.8 Navigational bronchoscopy. Split screen image demonstrating real-time endobronchial imaging adjacent to a virtual bronchoscope image and a three-dimensional map of the lesion and bronchial tree (courtesy of Mr Kelvin Lau, Barts Thorax Centre, London, UK).

key to allow the specialty to progress. The pioneers of yesterday have to teach the surgeons of tomorrow not only the technical and dexterous skills required but also the decision-making and innovative skills necessary for the field to continue to evolve. Training is often perceived as difficult, as trainers have less control over the trainees at the time of surgery and caseloads may be smaller, especially in centres where laparoscopic and robotic procedures are not common. However, trainees now rightly expect exposure to these procedures, and training systems should be adaptable for international exposure so that these techniques can be disseminated worldwide.

The predominant video and digital component of these new techniques opens the door for simulation approaches for training in these modalities, which have demonstrated benefits in reducing learning curves and in turn are aimed at improving patient outcomes. The ultimate goal for this educational approach is to develop expert surgeons through the 'totally safe' and 'risk-free' environment of simulation before they

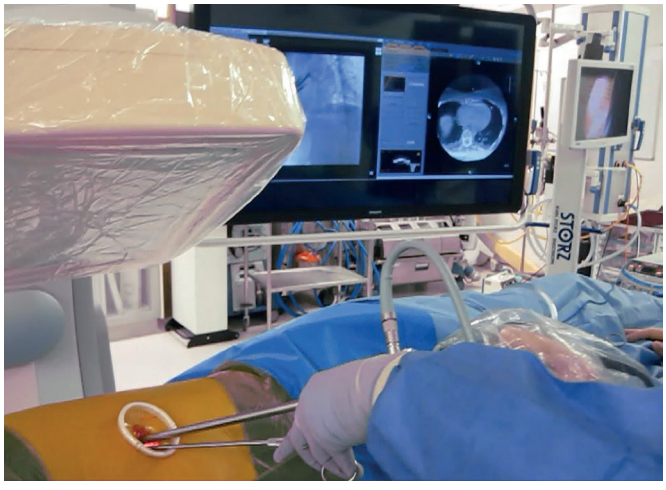

Figure 10.9 Image-guided video-assisted thoracoscopic surgery with the use of a navigationally placed fiducial marker to guide tumour resection (courtesy of Mr Kelvin Lau, Barts Thorax Centre, London, UK).

actually have to operate on patients. Indeed, both videoscopic and robotic platforms now have established simulation programs that are a prerequisite for surgical trainees. Modern robotic simulation modules are able to create an environment that mirrors console use (face validity) and subsequently provide hierarchical training compatible with the user's expertise. The combination of simulation with proficiency-based 'mastery' training may be the key to optimising the impact that simulation may have on the surgical learning curve and remains the subject of research in a range of surgical specialties.

With widespread uptake of minimal access surgery, trainees are now facing a new problem owing to lack of experience in open surgery. Surgeons must have sufficient open surgical experience to feel comfortable converting cases in the event of difficulty or emergency. A minimal access approach to a particular procedure may differ significantly in the order of operative steps and dissection technique. It is therefore vital that the new generation of surgeons continues to receive training in open surgery so that they can apply either technique as appropriate.

Advances in robotic surgery lend themselves to further AI integration, with potential advantages such as providing enhanced clinical decision support, warning of deviations from optimal workflow or detecting and overlaying potentially at-risk structures. In this way, artificially intelligent systems may streamline procedural technique, reduce error and improve patient outcomes. Intelligent operating theatres may provide automated optimisation of a wide range of ergonomic features such as table positioning, lighting and temperature, further facilitating procedural efficiency and effectiveness. In turn, more advanced artificial systems may also develop a degree of supervised autonomy whereby basic surgical procedures can be independently performed by the robotic system. Indeed, in a preclinical setting, the STAR (Smart Tissue Autonomous Robot) robotic system has demonstrated superiority over human surgeons in porcine bowel anastomosis.

Translation of such laboratory-based experiments to real-world surgery is not simple. Application requires detailed understanding of surgical workflow and integration of complex data. To provide a fully comprehensive, annotated training data set on which deep learning may be established, all devices and systems in the dynamic operating environment must be integrated, including operating room set-up, tool and camera usage and the variable patient and procedural factors. In addition there are complex questions in terms of data protection and confidentiality, not to mention the ethical considerations and accountability of autonomous or semi-autonomous robotic surgeons. The most promising elements of AI integration into minimal access surgery remain enhanced object detection, speech recognition, video characterisation and integration with next-generation technologies. Real-time metabolic profiling and tissue-level diagnosis may differentiate between cancerous and non-cancerous tissues on the basis of their metabolic signature. An example is the iKnife, which uses a rapid evaporative ionisation mass spectrometric (REIMS) technique to report tissue histology in real time by analysing aerosolised tissue during electrosurgical dissection.

Artificially intelligent systems also hold potential to dramatically improve the fidelity of simulation training in minimal access surgery, through the creation of a 'real-world' training environment based on the vast data accrued in their development. Such data may be used to create a dynamic simulation environment for any procedure, much more akin to that of 'real-life' surgery. This holds potential for a stepwise tutorial system similar to that of bedside teaching, with objective feedback provided against standardised proficiency benchmarks that can be easily integrated into national training programmes.

One major obstacle for minimally invasive technology remains the cost efficiency and device financing in an increasingly rationed global healthcare environment; this is an issue that will require surgical liaison with hospital management and national policy providers. Surgeons need to continue to have a dialogue, discussing their experiences and ideas in order to effectively progress minimal access surgery and continue to adopt novel technology. As technological advancements are adopted, carefully designed outcomes research is required to provide a clear evidence base to support changes to clinical practice. In this way the comparative effectiveness of novel minimal access technologies will be better understood in terms of both clinical outcomes and cost-effectiveness, allowing selection of those with the greatest potential to provide lasting improvements in patient care.

> The cleaner and gentler the act of operation, the less the patient suffers, the smoother and quicker his convalescence, the more exquisite his healed wound.
>
> Berkeley George Andrew Moynihan (1920)

Berkeley George Andrew Moynihan (Lord Moynihan), 1865–1936, Professor of Clinical Surgery, Leeds, UK. Moynihan felt that English surgeons knew little about the work of their colleagues both at home and abroad. Therefore, in 1909, he established a small travelling club which in 1929 became the Moynihan Chirurgical Club. It still exists today. He took a leading part in founding the *British Journal of Surgery* in 1913 and became the first chairman of the editorial committee until his death.

FURTHER READING

Athanasiou T, Ashrafian H, Rao C *et al*. The tipping point of robotic surgery in healthcare: from master–slave to flexible access bio-inspired platforms. *Surg Technol Int* 2011; **21**: 28–34.

Bhandari M, Zeffiro T, Reddiboina M. Artificial intelligence and robotic surgery: current perspective and future directions. *Curr Opin Urol* 2020; **30**(1): 48–54.

Bodenstedt S, Wagner M, Müller-Stich BP *et al*. Artificial intelligence-assisted surgery: potential and challenges. *Visc Med* 2020; **36**(6): 450–5.

Brodie A, Vasdev N. The future of robotic surgery. *Ann R Coll Surg Engl* 2018; **100**(Suppl 7): 4–13.

Hussain I, Cosar M, Kirnaz S *et al*. Evolving navigation, robotics, and augmented reality in minimally invasive spine surgery. *Global Spine J* 2020; **10**(2 Suppl): 22S–33S.

St John ER, Balog J, McKenzie JS *et al*. Rapid evaporative ionization mass spectrometry of electrosurgical vapours for the identification of breast pathology: towards an intelligent knife for breast cancer surgery. *Breast Cancer Res* 2017; **19**(1): 59.

Tan A, Ashrafian H, Scott AJ *et al*. Robotic surgery: disruptive innovation or unfulfilled promise? A systematic review and meta-analysis of the first 30 years. *Surg Endosc* 2016; **30**(10): 4330–52.